

## Effect of laser irradiation on the progression of skin cancer using carcinogen among hamsters

Kawthar Shurrab\*<sup>1</sup>, Nabil Kochaji<sup>2</sup>, WesamBachir<sup>3</sup>

1. Medical Physicist, PhD student of Higher Institute for Laser Research and Applications, Damascus University, Damascus, Syria.
2. PhD, Professor, Oral Pathologist, Dean of Faculty of Dentistry, Al-Sham University, Damascus, Syria.
3. Biomedical Photonics laboratory, Higher Institute for Laser Research and Applications, Damascus University, Damascus, Syria

### ARTICLE INFO

**Article type:**  
Original Article

**Article history:**

Received: Apr 06, 2018  
Accepted: Dec 02, 2018

**Keywords:**

Carcinogens  
Irradiation Power  
Skin Cancer  
Thermal Effect  
Diode Laser

### ABSTRACT

**Introduction:** Skin cancer has been increased day by day, but it can be cured if it diagnosed early. After reviewing the scientific literature about 980 nm diode laser, and its multiple advantages on skin diseases. We studied in this paper the effectiveness of this type of laser on the progression of skin cancer among hamsters which were exposed to carcinogen on the back.

**Material and Methods:** The carcinogenic solution of 9, 10-dimethyl-1, 2-benzanthracene was applied to the hamsters' skin on the back. A 980 nm Diode laser light with irradiation power of 0.5w and 1.0w and an exposure time of 100 sec were used in order to prevent the harmful thermal effect on surrounding tissue as studied in previous paper [1].

**Results:** According to the results, only one group of hamsters which was not consistently irradiated by laser gave rise to melanoma tumor. The other groups that were exposed to diode 980nm laser irradiation at different powers (i.e., 0.5w and 1.0w) and an exposure time of 100 sec showed no growth of skin cancer during the experiment.

**Conclusion:** The 980 nm Diode laser has an effect on delaying the onset of cancer and has had a role in the reduction of skin cancer lesions. However, further studies are required to test its inhibitory activities against carcinogenesis.

► Please cite this article as:

Shurrab K, Kochaji N, Bachir W. Effect of laser irradiation on the progression of skin cancer using carcinogen among hamsters. Iran J Med Phys 2019; 16: 314-318. 10.22038/ijmp.2018.30727.1354.

### Introduction

Yamagiwa used chemical carcinogenesis for the first time to produce cancer in experimental animals at Tokyo Imperial University in Japan during 1915 [2]. This was the beginning of studies on environmental chemical carcinogenesis. Afterward, Ichikawa et al. repeated the experiment by applying coal tar dissolved in benzene onto the ears of rabbits [3,4]. According to a study conducted by Tsutsui at Chiba Medical College, cancer began to develop in a shorter period of time by coal tar coating on mice skin. Moreover, the first pure chemical compound 1, 2, 5, 6-dibenzanthracene was utilized to produce skin cancer among rats in 1930 [5,6].

#### Melanoma

Melanoma is the most serious type of skin cancer, which develops in the cells responsible for producing melanin, a pigment that gives the skin its color. The melanoma may develop within the eye and rarely develops in the internal organs, such as the intestine [7].

It is not yet known exactly what causes different types of melanoma to occur, however, exposure to UV

rays from the sun can increase the risk of melanoma [8-9].

The avoidance of unnecessary exposure to sunlight may help prevent melanoma development [10]. Attention should also be to skin cancer warning signs to ensure the early detection of cancerous changes in the skin in order to treat tumors before they spread. Melanoma skin cancer can be treated successfully if it is diagnosed early [11,12].

Symptoms of melanoma may originate from anywhere on the body; however, skin areas that have been exposed to large amounts of sunlight, such as legs, arms, the back, and face are more likely to develop melanoma. Melanoma may also appear in areas that have not been exposed to much sunlight, such as feet, and hands or nail surfaces [13,14].

### Materials and Methods

As a carcinogen, 9, 10-dimethyl-1, 2-benzanthracene (DMBA) (Sigma-Aldrich, INC) was used in this study. Figure 1 illustrates the utilization of a 980nm diode laser (DioDent Micro is a trademark of Hoya ConBio) in order to test its effect on the progression of skin cancer.

\*Corresponding Author: E-mail: Sh\_kawther@yahoo.com

The experiment on animals was happened after intuitional ethical approval was obtained, according to Damascus university ethical committee decision no. 3164.

In total, 35 hamsters with the age range of 10-12 weeks were assigned into five groups (n=7), namely normal control (group 1), DMBA control (group 2), laser control (group 3), DMBA+ 980nm diode laser 0.5W (group 4), and DMBA+ 980nm Diode laser 1.0W (group 5).

The hamsters were kept in plastic basins in good health conditions at room temperature. In addition, they were fed with barley, mullet, bran, wheat, maize, lettuce, and water continuously. Care was taken for the basin floor using a layer of sawdust to absorb moisture [2,15].

The DMBA was mainly used as a carcinogen on hamster skin. The solutions were prepared by dissolving every 6 g of DMBA in 100 ml of mineral oil over the heat. It was then stirred for half an hour, cooled and packed in plastic containers to be ready for use [16].

The solutions were applied topically on hamsters' skin on the back according to the following procedure.

The treated area was shaved with an electric clipper prior to the experiment and periodically reshaved during the experiment. Subsequently, the solution was applied topically with a clean brush 3 times a week on the target area of the hamster back. In the next stage, the hamsters were exposed to sunlight for 4 h three times a week.

After the hamsters were exposed to carcinogen, the 980 nm diode laser (power: 0.5w and 1w) was applied once a week until the end of the experiment. Moreover, the animals were checked at weekly intervals and monitored until they died spontaneously. Otherwise, they were sacrificed at the scheduled intervals during the experiment.

The hamsters were anesthetized prior to sacrifice using chloroform.



Figure 1. 980nm diode laser

### Results

The control group with normal skin showed no change in behavior during the experiment. This indicates the validity of experimental animals breeding and the mechanism used in the experiment. Figure 2 (A and B) depicts the symptoms, such as slight desquamation, minor light gray spots in the area of applied carcinogen, and weak hair growth in group two.

This group was exposed to 9,10-dimethyl-1, 2-benzanthracene in mineral oil three times a week and the mentioned symptoms began to appear during the first few weeks following the application of the carcinogen it appeared clearly in week 12.

Within the 16<sup>th</sup> week, numerous minute black spots appeared. The spots were scattered throughout the treated area as shown in Figure 3 (A and B). Increased aggressive behavior and pigmented lesions with irregular shapes and weak hair growth were observed within the 20<sup>th</sup> week of the experiment (Figure 4, A and B).

The mean latency calculated for all melanoma varied from 12<sup>th</sup> to 24<sup>th</sup> weeks (Table 1). After week 16, a hamster was sacrificed from each group every four week until the last remained animal was sacrificed on the 36<sup>th</sup> week (Table 2).

Table1. Results of the application of carcinogen on hamster skin

No. Weeks	DMBA Control	980nm Diode Laser Control	DMBA+ 980nm Diode Laser 0.5w	DMBA+ 980nm Diode Laser 1.0w
4	N	N	N	N
8	N	N	N	N
12	Light pigmented lesions, and weak hair growth	N	N	N
16	Numerous minute black spots scattered in treated area, and weak hair growth	N	N	N
20	Increased aggressive behavior and pigmented lesions with irregular shapes, and weak hair growth	N	N	N
24	Increased pigmented lesions and aggressive behavior, and weak hair growth	N	N	N
26	Aggressive behavior and pigmented lesions, and weak hair growth	N	N	N
28	Aggressive behavior and pigmented lesions, and weak hair growth	N	N	N
32	Aggressive behavior and pigmented lesions, and weak hair growth	N	N	N
36	Aggressive behavior and increased pigmented lesions, and weak hair growth	N	N	N

N: Normal

Table 2. Number of sacrificed hamsters after week 16 (every four week one hamster was sacrificed)

No. Groups	No. Hamsters	survival rate vs. weeks								
		4	8	12	16	20	24	28	32	36
Group 1	7	7	7	7	6	5	4	3	2	1
Group 2	7	7	7	7	6	5	4	3	2	1
Group 3	7	7	7	7	6	5	4	3	2	1
Group 4	7	7	7	7	6	5	4	3	2	1
Group 5	7	7	7	7	6	5	4	3	2	1

Group1: Normal Control

Group2: DMBA control

Group3: Laser control

Group4: DMBA+ 980nm Diode laser 0.5W

Group5: DMBA+ 980nm Diode laser 1.0W

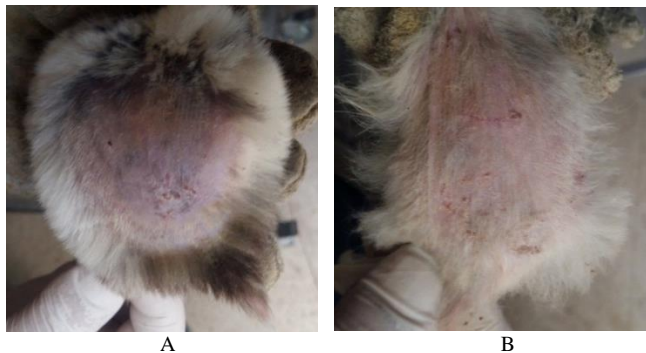


Figure 2. Weak hair growth and the appearance of light gray pigmented lesion at week 12 (A and B)

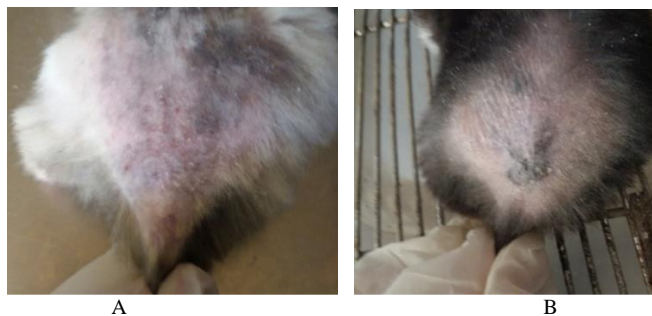


Figure 3. Increased appearance of black pigmented lesions at week 16 (A and B)

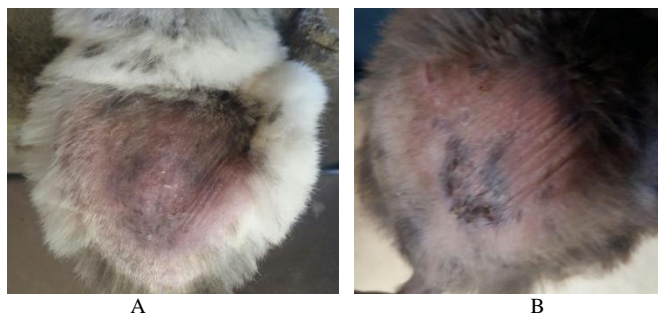


Figure 4: Increased and aggressive pigmented lesions with irregular shapes at week 20 (A and B)

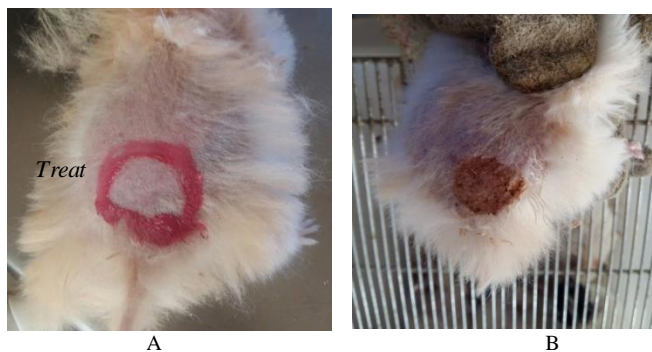

Figure 5. Redness on the surface of the skin after exposing the area to the laser as a result of hyperthermia (A), Disappearance of redness after two days (B)

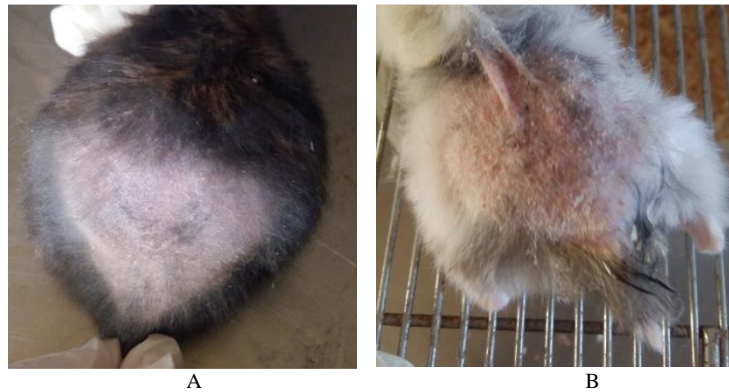


Figure 6. Reduction in the size and color of dark spots after stopping carcinogen and laser irradiation of 0.5w at week 24 (A and B)

One of the groups was subjected to DMBA and exposed to 980nm diode laser (0.5W) for 100s. The findings showed redness on the surface of the skin after irradiation as a result of heating of the skin surface (Figure 5 A). Redness disappeared two days later and there was no change in the surface of the skin in Figure 5(B).

Another group of hamsters was isolated after the appearance of pigmented lesions at week 20. The application of carcinogens was stopped and the hamsters were exposed to 980nm diode laser (0.5w) once a week for eight sessions. This results in the reduction of the size and color of dark spots (Figure 6, A and B).

## Discussion

Modern techniques, such as combined radiofrequency ablation, chemotherapy, and radiation therapy are used to maximize tumor cell death, increase end-point survival, and optimize patient safety [17]. In addition, lasers are widely used in various medical fields, such as cosmetic surgery. Due to their clinical advantages and bacterial reduction in surgical sites, lasers achieve maximum levels of patient comfort.

Moreover, the laser is used in cancer treatment because of its ability to reduce and destroy cancer cells [11].

According to the review of the scientific literature on 980 nm Diode laser, its multiple advantages were confirmed in terms of reliability, ease of use, and affordability by the patient. In addition, the effectiveness and safety of this type of laser were evaluated to determine its effect on the inhibition and treatment of skin cancer. However, tumor thermotherapy is a method of cancer treatment in which cancer cells are killed by exposing the body tissues to high temperatures.

The effect of 980nm diode laser was evaluated in this study while applying the DMBA on the skin of the hamsters. Only one group of hamsters which was not irradiated by laser consistently gave rise to skin cancer. The symptoms appeared at week 12 with increased aggressive behavior and pigmented lesions with irregular shape and weak hair growth until the end of the experiment.

Groups 4 and 5 were exposed to diode 980nm laser irradiation power of 0.5w and 1.0w for 100s, respectively. The results showed no change in the skin, except for redness that disappeared after two days of laser exposure. The hamsters which were exposed to the Diode 980nm laser power 0.5w with no carcinogen any more showed a reduction in size and color of dark lesions.

The experiment lasted 36 weeks until the last remained hamster was sacrificed.

## Conclusion

The 980nm Diode laser has a significant effect on delaying the onset of cancer and has had a role in the reduction of skin cancer lesions. However, further studies are required to examine its effect on the inhibition of carcinogenesis and its effectiveness when used in conjunction with other modalities.

## Acknowledgment

Hereby, the authors extend their gratitude to all colleagues at Damascus University and Higher Institute for Laser Research and Applications who cooperated in this study.

## References

1. Kawthar Shurrab, Nabil Kochaji, Wesam Bachir, "Development of Temperature Distribution and Light Propagation Model in Biological Tissue Irradiated by 980 nm Laser Diode and Using COMSOL Simulation", *Journal of Laser in Medical Science*, Vol 8, No 3(2017).
2. Takashi Sugimura, "Studies on environmental chemical carcinogenesis in Japan", *Science*, vol. 233, 1986, p. 312+. Academic OneFile.
3. PhillippesHubik, HilippesHubik, Giuseppe Pietra, AndgiuseppedellAporta, "Studies of Skin Carcinogenesis in the Syrian Golden Hamster", July 20,1995
4. Chen W.R.; Richey J.W.; Bartles K.E; Liu H. and Nordddquist R.E. (2002), "Effect of Different Components of Laser Immunotherapy In Treatment of Metasstatic Tumors In Rats". *Cancer Res* 62:4295-4299.

5. Chong LP , Ozler SA , de Queiroz JM Jr , Liggett PE, “Indocyanine green-enhanced diode laser treatment of melanoma in a rabbit model” , Europe PMC, Jan 1993, 13(3):251-259.
6. HARRYS. N. GREENE, “ A Spontaneous Melanoma in the Hamster with a Propensity for Amelanotic Alteration and Sarcomatous Transformation during Transplantation ” , American Association for Cancer Research, 1958, Vol. 18, May.
7. C.S. Souza MD, PhD,a,\*, L.B.A. Felicio a, J. Ferreirab, C. Kurachib,M.V.B. Bentleyc, A.C. Tedescod, V.S. Bagnatob” Long-term follow-up of topical 5-aminolaevulinic acid photodynamic therapy diode laser single session for non-melanoma skin cancer” Photodiagnosis and Photodynamic Therapy (2009) 6, 207–213.
8. Cynthia S.Cook, David A. Wilkie, “Treatment of presumed iris melanoma in dogs by diode laser photocoagulation: 23 cases” , Veterinary Ophthalmology, Volume 2, Issue 4 December 1999, Pages 217-225.
9. Marmur ES, Schmults CD, Goldberg DJ.” A Review Of Laser And Photodynamic Therapy For The Treatment Of Nonmelanoma Skin Cancer. Dermatol Surg” 2004, 30(2 Pt 2):264–71.
10. Ekaterina I. Galanzha, Evgeny V. Shashkov, Paul M. Spring, James Y. Suen and Vladimir P. Zharov, “In vivo, Noninvasive, Label-Free Detection and Eradication of Circulating Metastatic Melanoma Cells Using Two-Color Photoacoustic Flow Cytometry with a Diode Laser” American Association for Cancer Research. 2009, Volume 69, Issue 20
11. Apollonia DESIATE, Stefania CANTORE, Domenica TULLO, Giovanni PROFETA, Felice Roberto GRASSI, and Andrea BALLINI,” 980 nm diode lasers in oral and facial practice: current state of the science and art” , international journal of medical science.
12. Huaxu Liu MD, PhD, Yongyan Dang PhD, Zhan Wang MD, PhD, Xinyu Chai PhD, Qiushi Ren PhD, “Laser induced collagen remodeling: A comparative study in vivo on mouse model” , Lasers In Surgery And Medicine, Volume 40, Issue 1 January 2008 Pages 13-19.
13. Romanos GE, Henze M, Banihashemi S, Parsanejad HR, Winckler J, Nentwig GH. Removal of epithelium in periodontal pockets following diode (980 nm) laser application in the animal model: an in vitro study. Photomed Laser Surg. 2004 Jun; 22(3):177-83. [PubMed].
14. Richard Rox Anderson, “Lasers in Dermatology–A Critical Update
15. Authors” The journal of dermatology, November 2000, Volume 27, Issue 11, Pages 700-705.
16. Clare Horkan, BCh Kshitij Dalal, Jeffrey A. Coderre,” Reduced Tumor Growth with Combined Radiofrequency Ablation and Radiation Therapy in a Rat Breast Tumor Model” , 2005; 235:81-88
17. Romanos GE, Henze M, Banihashemi S, Parsanejad HR, Winckler J, Nentwig GH. Removal of epithelium in periodontal pockets following diode (980 nm) laser application in the animal model: an in vitro study. Photomed Laser Surg. 2004 Jun; 22(3):177-83. [PubMed]
18. Fei Tang, Ye Zhang, Juan Zhang, Junwei Guo,” Assessment of the efficacy of laser hyperthermia and nanoparticle-enhanced therapies by heat shock protein analysis” , 2014 AIP Advances 4, 031334.